

Unicompartmental knee arthroplasty: Is robotic technology more accurate than conventional technique?



Mustafa Citak^a, Eduardo M. Suero^a, Musa Citak^a, Nicholas J. Dunbar^b, Sharon H. Branch^c, Michael A. Conditt^c, Scott A. Banks^b, Andrew D. Pearle^{a,*}

^a Department of Orthopaedic Surgery, Hospital for Special Surgery, New York, NY, United States

^b Orthopedic Biomechanics Laboratory, University of Florida, Gainesville, FL, United States

^c Mako Surgical Corp., Ft. Lauderdale, FL, United States

ARTICLE INFO

Article history:

Received 2 March 2012

Received in revised form 30 October 2012

Accepted 1 November 2012

Keywords:

Robotic-assisted

Unicompartmental knee arthroplasty

Navigation

Accuracy

ABSTRACT

Background: Robotic-assisted unicompartmental knee arthroplasty (UKA) with rigid bone fixation "can significantly improve implant placement and leg alignment. The aim of this cadaveric study was to determine whether the use of robotic systems with dynamic bone tracking would provide more accurate UKA implant positioning compared to the conventional manual technique.

Methods: Three-dimensional CT-based preoperative plans were created to determine the desired position and orientation for the tibial and femoral components. For each pair of cadaver knees, UKA was performed using traditional instrumentation on the left side and using a haptic robotic system on the right side. Postoperative CT scans were obtained and 3D-to-3D iterative closest point registration was performed. Implant position and orientation were compared to the preoperative plan.

Results: Surgical RMS errors for femoral component placement were within 1.9 mm and 3.7° in all directions of the planned implant position for the robotic group, while RMS errors for the manual group were within 5.4 mm and 10.2°. Average RMS errors for tibial component placement were within 1.4 mm and 5.0° in all directions for the robotic group; while, for the manual group, RMS errors were within 5.7 mm and 19.2°.

Conclusions: UKA was more precise using a semiactive robotic system with dynamic bone tracking technology compared to the manual technique.

© 2012 Elsevier B.V. All rights reserved.

1. Introduction

Unicompartmental knee arthroplasty (UKA) was introduced in the early 1970s and is nowadays commonly used for the treatment of isolated compartmental osteoarthritis of the knee [1,2]. In 1971, Gunston et al. presented a concept and design for a polycentric knee replacement based on the biomechanics of normal knee movement for either a bicompartmental or unicompartmental arthroplasty [3]. However, UKA did not gain wide acceptance due to high failure rate and poor outcome [4].

Nevertheless, recent improvements in implant design, minimally invasive techniques, bone-sparing strategies, expanded indications and early rehabilitation have all contributed to a renewed enthusiasm for UKA. It has been shown to be a good and less invasive alternative to total knee arthroplasty (TKA) in selected patients [5]. Advantages of UKA include better postoperative range of motion, less soft tissue

dissection, preservation of bone stock, minimal blood loss, faster recovery, lower complication rates and more physiological function [5,6].

However, UKA does have some disadvantages. Early failure of femoral and tibial components has been reported [7–10]. Berend et al. concluded that body mass index greater than 32 increased failure rates [7]. But it has been failures attributed to overcorrection and undercorrection that have received the most attention [11–14].

The use of computer assisted surgery systems in UKA has resulted in improved postoperative alignment, reduction of outliers and better postoperative clinical results [15,16]. Cobb et al. reported that robot-assisted placement of UKA components with rigid intraoperative bone stabilization was more accurate than traditional techniques and that, subsequently, clinical outcomes were improved [17]. Since then, robotic systems with dynamic bone tracking have been evolved. However, it remains to be shown whether these newer systems hold the same accuracy advantages previously demonstrated with robotic systems using rigid fixation.

The aim of this cadaveric study was to determine whether the use of robotic systems with dynamic bone tracking would provide more accurate UKA implant positioning compared to the conventional manual technique.

* Corresponding author. Tel.: +1 212 774 2878.
E-mail address: PearleA@HSS.edu (A.D. Pearle).

2. Materials and methods

2.1. Preoperative planning

Preoperative CT scans were performed with each specimen in the supine position. Five-millimeter slices were taken through the hip and ankle, while one-millimeter slices were taken through the knee joint. The data were saved in DICOM 3 (Digital Imaging and Communications in Medicine; Rosslyn, VA) format and then transferred into the tactile guidance system (TGS) software (MAKO Surgical Corp., Fort Lauderdale, FL). Bone surfaces were segmented using the software to produce a three-dimensional (3D) model. In all knees, a three-dimensional CT-based preoperative plan was created to determine the desired position and orientation for the tibial and femoral components.

2.2. Operative technique

Six fresh-frozen hip-to-toe cadaver specimens (12 knees) were used in this study. Specimens were thawed for 48 h prior to testing and were then placed supine on an operating room table [18]. A single surgeon performed medial unicompartmental knee arthroplasty on each knee using a tissue-sparing approach. For each cadaver pair of knees, UKA was performed using traditional instrumentation on the left side [19], and using a haptic robotic system acting as a virtual cutting guide to perform the robot-assisted UKA on the right side [20]. The goal of alignment with the onlay tibial component is to reproduce the native posterior sagittal slope and make a coronal resection at 90° relative to the mechanical tibial axis. Reference optical arrays were placed into the distal femur and proximal tibia using Steinman pins and also mounted on the robotic arm. The end of the arm was equipped with a bone-resecting burr. The end effector was grasped by the surgeon, and then moved within the surgical site. While inside the predetermined desired volume of bone to be resected, the robotic arm operated without offering any resistance. As the burr approached the predetermined boundaries, the robotic arm resisted that motion and kept the burr within the accepted volume (Fig. 1). The trial implants were then impacted. Finally, the trial implants were removed and the final implants were cemented. For all arthroplasties, Restoris Onlay prostheses (MAKO Surgical Corporation, Fort Lauderdale, FL) were used. After final implantation, a final ROM of the knee was measured using the system.

2.3. Outcome measures

Postoperative CT scans were obtained from all knees with the same scan protocol used preoperatively. Three-dimensional component placement accuracy was assessed by comparing the preoperative plan with the postoperative implant placement in all cases. Utilizing 3D registration, the femoral component position was determined in the same coordinate system as the preoperative plan [21]. Bone and implant models were obtained from postoperative CT scans taken immediately following surgery. The CT scan protocol included 200 slices taken through the knee (approximately 10 cm above and below the knee center) with a maximum slice thickness of 1 mm. Combined bone and implant 3D models were created by segmenting the CT images using active contour models with image intensity threshold filtering (ITK-SNAP, www.itksnap.org). Some manual editing was required during segmentation to correct contours for streaking artifacts from the metallic implants. Previous research showed that RMS differences between CT-based and laser scan implant position measurements were within 0.8 mm and 0.9° and 0.9 mm and 1.7° in all directions for the femoral and tibial components, respectively [21]. A 3D-to-3D iterative closest point registration (ICP) procedure was performed with commercially licensed software (Geomagic, Geomagic Inc.). The ICP procedure attempts to find the rigid transformation that best aligns a

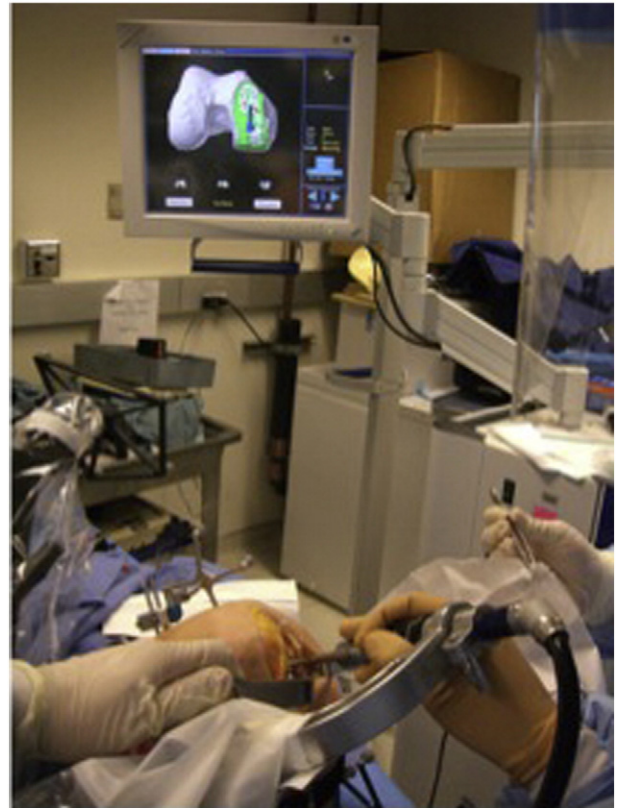

Fig. 1. Experimental setup showing the Tactile Guidance System.

cloud of points with a geometric model, using a least-squares method where the sums of squares of distances between the sample pairs are minimized over all the rigid motions that could realign the two objects. The closest points on the reference were re-computed and a new transformation matrix was established. The implant was then directly compared to the preoperative plan for medial/lateral, anterior/posterior, superior/inferior, flexion/extension, varus/valgus and internal/external rotation positions and orientations (Fig. 2).

2.4. Statistical analysis

Statistical analysis was carried out using Stata/IC 10.1 for Windows (StataCorp LP, College Station, TX, USA). The Shapiro–Wilk test was performed, which confirmed that the data had normal distribution ($P > 0.05$). Femur and tibial implant placement errors for both the manual group and the robotic group were analyzed by comparing the preoperatively planned position with postoperatively achieved results. The root-mean-square error (RMSE) was used to quantify alignment errors to avoid skewing results as a result of averaging positive and negative errors.

3. Results

Table 1 shows mean values, range and RMSE for each outcome measure studied. In general, less variability in implant alignment was seen in the robotic group compared to the manual group.

Surgical RMS errors for femoral component placement were within 1.9 mm and 3.7° in all directions of the planned implant position for the robotic group, while RMS errors for the manual group were within 5.4 mm and 10.2°.

Average RMS errors for tibial component placement were within 1.4 mm and 5.0° in all directions for the robotic group; while, for the manual group, RMS errors were within 5.7 mm and 19.2°.

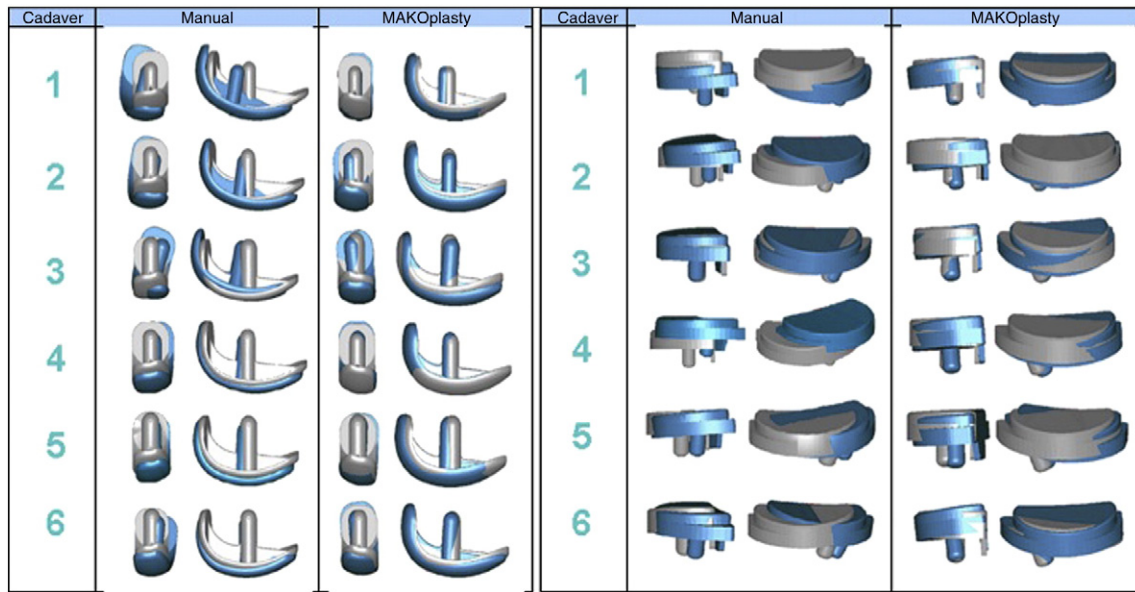


Fig. 2. Graphical overlays of the plan (grey) and implanted (blue) tibial and femoral component positions are given in this figure for the bilateral six pairs of knees.

4. Discussion

Unicompartmental knee arthroplasty is an alternative treatment option in young and active patients with severe compartmental osteoarthritis, who wish to delay or even forego a total knee arthroplasty [5]. Well-placed UKA implants can provide durable and excellent functional results. Computer assisted surgery technology in UKA has resulted in improved postoperative alignment, reduction of outliers and better postoperative clinical results [15,16]. Nevertheless, accurate reproduction of a preoperative plan remains a challenge in UKA.

This cadaveric study was performed to determine whether the use of robotic systems with dynamic bone tracking would provide more accurate UKA results compared to the conventional manual technique. The results of this study demonstrate that it is possible to achieve significant accuracy improvements with robot-assisted techniques allowing free bone movement compared to manual techniques.

Previous clinical studies have shown promising early results in implant placement and leg alignment, with the combination of computer-assisted navigation and robotic technology in UKA [17,22]. Rodriguez et al. showed significant improvement in implant placement and leg alignment using the Acrobot system in a clinical, prospective study. No outliers were registered using the robotic system, while only 40%

of cases in the conventional group were within the targeted alignment limits [17,22]. Cobb et al. confirmed these results in a larger prospective, randomized controlled trial using the same robotic system. However, these methods employed rigid intraoperative stabilization of the bones in a stereotactic frame. Robotic systems have now evolved to include dynamic bone tracking technologies so that rigid fixation is no longer required.

Pearle et al. reported the first clinical series of ten implanted inlay UKAs using a semiactive robotic system with dynamic bone tracking technology [23]. No outliers or complications were noted in the study. The difference between the planned and the intraoperative tibiofemoral angle was less than 1° [23]. Sinha reported on the outcomes of robotic arm-assisted unicompartmental knee arthroplasty [24]. He concluded that robotically assisted UKA has extremely accurate bone preparation relative to the preoperative plan and is a reliably accurate tool. Additionally, robotic UKA has similar results regarding complications, patient function and surgeon learning curve compared to conventional UKA. In a recent study, Lonner et al. compared the postoperative radiographic alignment of the tibial component with the preoperatively planned position with and without the use of robotics and found higher RMS error of the posterior tibial slope and higher varus/valgus RMS error with the conventional technique [25].

Table 1
Comparison of femoral and tibial component RMSE between the robotic and manual groups.

	Robotic			Manual		
	Mean	Range	RMSE	Mean	Range	RMSE
Femoral component						
Medial/lateral (mm)	0.1	−2.24–1.13	1.1	1.3	−1.51–6.79	3.2
Anterior/posterior (mm)	−1.6	−3.30 to −0.37	1.9	−4.6	−9.75 to −0.87	5.4
Superior/inferior (mm)	−0.4	−1.59–1.09	0.8	−1.4	−2.81–0.76	1.9
Flexion/extension (°)	2.9	−2.08–5.16	3.2	7.6	0.01–13.3	8.9
Varus/valgus (°)	2.0	−7.06–6.75	3.7	7.6	−0.98–18	10.2
Internal/external rotation (°)	−1.1	−1.99–1.02	1.6	−3.1	−13.24–6.48	7.4
Tibial component						
Medial/lateral (mm)	−0.6	−1.97–1.84	1.4	−1.3	−2.48–1.43	1.9
Anterior/posterior (mm)	−0.7	−2.08–0.19	1.1	5.0	1.06–9.87	5.7
Superior/inferior (mm)	0.1	−0.72–1.09	0.6	0.9	−4.44–5.32	3.1
Flexion/extension (°)	0.9	−2.08–2.66	1.7	3.6	−1.31–7.81	4.6
Varus/valgus (°)	−4.9	−7.06 to −3.74	5.0	−2.9	−6.00–0.17	3.9
Internal/external rotation (°)	0.7	−7.01–4.20	4.0	−18.0	−31.67 to −6.96	19.2

There are several limitations to our study. All procedures were performed by the same surgeon. Hence, no information on the intersurgeon variability associated with each technique can be provided. However, the operating surgeon was a senior attending orthopedic surgeon, who was experienced in robotic-assisted UKA. Another limitation of our study, as with most cadaveric studies, was that a small number of specimens were tested. General drawbacks of this robotic system are the high initial cost of the system and further maintenance costs, as well as additional time for the setup of the system in the operating room and for the procedure itself. Preoperative CT scan and preoperative planning further increase time, effort and cost.

In conclusion, in our cadaveric study, unicompartmental knee arthroplasty was more precise using a semiactive robotic system with dynamic bone tracking technology compared to the conventional manual technique. We believe that robotic technology could be of great benefit for precise implant planning and placement. The evolution of surgical robotics might help in developing a more precise minimally-invasive approach in UKA. However, additional larger experimental studies are required to verify our findings. Also, further clinical studies with mid- and long-term outcomes are warranted to establish whether the improved accuracy will influence long-term outcomes.

Conflict of interest

No institutional or research support was provided for this study for the following authors: Mustafa Citak, Eduardo M. Suero, Musa Citak, Andrew D. Pearle and Nicholas J. Dunbar. These authors have no professional or financial affiliations that may have biased this study. The authors “Sharon H. Branch and Michal A. Conditt” are paid employees for Mako Surgical Corp. The author “Scotts A. Banks” is a paid consultant for DJO Surgical; is an unpaid consultant for Smith & Nephew, Scientific Advisory Board Iconacy, Scientific Advisory Board; and receives research support from DJO Surgical, MAKO Surgical and Smith & Nephew.

References

- [1] Berger RA, Nedeff DD, Barden RM, Sheinkop MM, Jacobs JJ, Rosenberg AG, et al. Unicompartmental knee arthroplasty. Clinical experience at 6- to 10-year followup. *Clin Orthop Relat Res* 1999;50:60.
- [2] Suggs JF, Li G, Park SE, Sultan PG, Rubash HE, Freiberg AA. Knee biomechanics after UKA and its relation to the ACL—a robotic investigation. *J Orthop Res* 2006;24:588–94.
- [3] Gunston FH. Polycentric knee arthroplasty. Prosthetic simulation of normal knee movement. *J Bone Joint Surg Br* 1971;53:272–7.
- [4] Insall J, Aglietti P. A five to seven-year follow-up of unicondylar arthroplasty. *J Bone Joint Surg Am* 1980;62:1329–37.
- [5] Ohdera T, Tokunaga J, Kobayashi A. Unicompartmental knee arthroplasty for lateral gonarthrosis: midterm results. *J Arthroplasty* 2001;16:196–200.
- [6] Koskinen E, Paavolainen P, Eskelinen A, Harilainen A, Sandelin J, Ylinen P, et al. Medial unicompartmental knee arthroplasty with Miller–Galante II prosthesis: mid-term clinical and radiographic results. *Arch Orthop Trauma Surg* 2009;129:617–24.
- [7] Berend KR, Lombardi Jr AV, Mallory TH, Adams JB, Groseth KL. Early failure of minimally invasive unicompartmental knee arthroplasty is associated with obesity. *Clin Orthop Relat Res* 2005;440:60–6.
- [8] Collier MB, Eickmann TH, Sukezaki F, McAuley JP, Engh GA. Patient, implant, and alignment factors associated with revision of medial compartment unicondylar arthroplasty. *J Arthroplasty* 2006;21:108–15.
- [9] Furnes O, Espehaug B, Lie SA, Vollset SE, Engesaeter LB, Havelin LI. Failure mechanisms after unicompartmental and tricompartmental primary knee replacement with cement. *J Bone Joint Surg Am* 2007;89:519–25.
- [10] Mariani EM, Bourne MH, Jackson RT, Jackson ST, Jones P. Early failure of unicompartmental knee arthroplasty. *J Arthroplasty* 2007;22:81–4.
- [11] Hernigou P, Deschamps G. Alignment influences wear in the knee after medial unicompartmental arthroplasty. *Clin Orthop Relat Res* 2004;161–5.
- [12] Hernigou P, Deschamps G. Posterior slope of the tibial implant and the outcome of unicompartmental knee arthroplasty. *J Bone Joint Surg Am* 2004;86-A:506–11.
- [13] Jeer PJ, Keene GC, Gill P. Unicompartmental knee arthroplasty: an intermediate report of survivorship after the introduction of a new system with analysis of failures. *Knee* 2004;11:369–74.
- [14] Ridgeway SR, McAuley JP, Ammeen DJ, Engh GA. The effect of alignment of the knee on the outcome of unicompartmental knee replacement. *J Bone Joint Surg Br* 2002;84:351–5.
- [15] Buckup K, Linke LC, Hahne V. Minimally invasive implantation and computer navigation for a unicondylar knee system. *Orthopedics* 2007;30:66–9.
- [16] Molfetta L, Caldo D. Computer navigation versus conventional implantation for varus knee total arthroplasty: a case–control study at 5 years follow-up. *Knee* 2008;15:75–9.
- [17] Cobb J, Henckel J, Gomes P, Harris S, Jakopec M, Rodriguez F, et al. Hands-on robotic unicompartmental knee replacement: a prospective, randomised controlled study of the acrobot system. *J Bone Joint Surg Br* 2006;88:188–97.
- [18] Moon DK, Woo SL, Takakura Y, Gabriel MT, Abramowitch SD. The effects of refreezing on the viscoelastic and tensile properties of ligaments. *J Biomech* 2006;39:1153–7.
- [19] Repicci JA, Eberle RW. Minimally invasive surgical technique for unicondylar knee arthroplasty. *J South Orthop Assoc* 1999;8:20–7 [discussion 27].
- [20] Roche M, O’Loughlin PF, Kendoff D, Musahl V, Pearle AD. Robotic arm-assisted unicompartmental knee arthroplasty: preoperative planning and surgical technique. *Am J Orthop (Belle Mead NJ)* 2009;38:10–5.
- [21] Dunbar NJ, Roche MW, Park BH, Branch SH, Conditt MA, Banks SA. Accuracy of dynamic tactile-guided unicompartmental knee arthroplasty. *J Arthroplasty* 2012;27:803–8 [e1].
- [22] Rodriguez F, Harris S, Jakopec M, Barrett A, Gomes P, Henckel J, et al. Robotic clinical trials of uni-condylar arthroplasty. *Int J Med Robot* 2005;1:20–8.
- [23] Pearle AD, O’Loughlin PF, Kendoff DO. Robot-assisted unicompartmental knee arthroplasty. *J Arthroplasty* 2010;25:230–7.
- [24] Sinha RK. Outcomes of robotic arm-assisted unicompartmental knee arthroplasty. *Am J Orthop (Belle Mead NJ)* 2009;38:20–2.
- [25] Lonner JH, John TK, Conditt MA. Robotic arm-assisted UKA improves tibial component alignment: a pilot study. *Clin Orthop Relat Res* 2010;468:141–6.